

Assessment Of Role Of Proximal Femoral Nail In Management Of Intertrochanteric Femur Fracture

Dr. Ravindra B Gunaki¹, Dr. Nishant K Gaonkar², Dr. Sandeep Patil³

¹Professor, Department of orthopaedics, Krishna Institute of Medical Sciences, Karad, Maharashtra, India

^{2,3}Associate Professor, Department of orthopaedics, Krishna Institute of Medical Sciences, Karad, Maharashtra, India

Corresponding author: Dr. Sandeep Patil, Associate Professor, Department of orthopaedics, Krishna Institute of Medical Sciences, Karad, Maharashtra, India

ABSTRACT

Background: Fracture intertrochanteric femur is a most common fracture of hip especially in elderly. Proximal femoral nail is useful in intertrochanteric femoral fractures. The present study was conducted to assess role of proximal femoral nail in management of intertrochanteric femur fracture.

Materials & Methods: 62 patients of intertrochanteric femur fracture of both genders were treated with proximal femoral nail. Parameter such as mode of injury, side, fracture subtype and outcome based on Kyle's criteria were recorded.

Results: Out of 62 patients, males were 40 and females were 22. OTA fracture type was 31 A1 in 18, 31A2 in 24 and 31 A3 in 20 cases. Mode of injury was RTA in 56, fall in 19 and others in 10. Laterality was left in 37 and right in 48. Kyle's criteria was excellent in 30, good in 16, fair in 14 and poor in 2 cases. The difference was significant ($P < 0.05$). Complications were failure to insert distal screw in 2, Z- effect in 1, inadequate reduction in 3 and varus deformity in 1 case. The difference was significant ($P < 0.05$).

Conclusion: Proximal femoral nail is a good minimally invasive stable fixation option with minimal soft tissue handling for unstable intertrochanteric fractures. Patients treated by proximal femoral nailing showed good functional outcome.

Keywords: femoral nail, intertrochanteric femur, Hip

Introduction

Fracture intertrochanteric femur is a most common fracture of hip especially in elderly having male to female ratio of 3:1 with porotic bones usually due to low energy trauma.¹ Intertrochanteric Femur fractures comprise approximately 50% of all hip fracture caused by low intensity injury.²

The primary goal of the treatment has to be early mobilization to avoid secondary complications. Various operative procedures with different implants have been described for

the treatment of intertrochanteric fractures.³ Treatment options include dynamic hip screw (extramedullary fixation), gamma nail (intramedullary fixation), and proximal femoral nail (PFN) (intramedullary fixation).⁴ The hip screw has been considered the device of choice but has been associated with complications such as collapse of the femoral neck, leading to loss of hip offset, and shortening of the leg. Although some such sliding is expected, too much shortening is detrimental to hip function.⁵

PFN greatly reduces the lever arm distance and intramedullary location provides buttress

against lateral displacement and reduces bending strain on the implant, so compared with Dynamic hip screw. Proximal femoral nail (PFN) devised by AO/ASIF group has proven to be a stable implant in peritrochanteric, intertrochanteric or subtrochanteric femoral fractures.⁶ The present study was conducted to assess role of proximal femoral nail in management of intertrochanteric femur fracture.

Materials & Methods

The present study comprised of 62 patients of intertrochanteric femur fracture of both

genders. All gave their written consent for the participation in the study.

Data such as name, age, gender etc. was recorded. A thorough clinical examination was carried out. All patients with intertrochanteric femur fracture were treated with proximal femoral nail. Parameter such as mode of injury, side, fracture subtype and outcome based on Kyle's criteria

were recorded. Data thus obtained were subjected to statistical analysis. P value < 0.05 was considered significant.

Results

Table I Distribution of patients

Total- 62		
Gender	Males	Females
Number	40	22

Table I shows that out of 62 patients, males were 40 and females were 22.

Table II Assessment of parameters

Parameters	Variables	Number	P value
OTA fracture type	31 A1	18	0.94
	31A2	24	
	31 A3	20	
Mode of injury	RTA	36	0.89
	Fall	15	
	Others	11	
Laterality	Left	34	0.91
	Right	28	
Kyle's criteria	Excellent	30	0.04
	Good	16	
	Fair	14	
	Poor	2	

Table II, graph I shows that OTA fracture type was 31 A1 in 18, 31A2 in 24 and 31 A3 in 20 cases. Mode of injury was RTA in 36, fall in 15 and others in 11. Laterality was left in 34 and right in 28. Kyle's criteria was excellent in 30,

good in 16, fair in 14 and poor in 2 cases. The difference was significant (P< 0.05).

Graph I Assessment of parameters

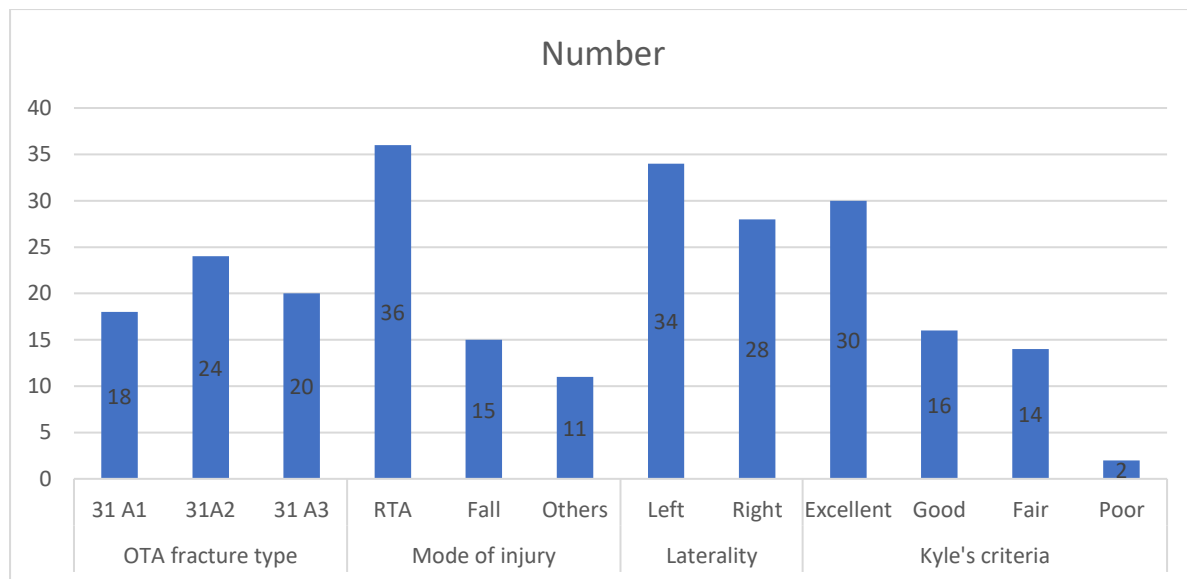


Table III Table III Assessment of complications

Complications	Number	P value
failure to insert distal screw	2	0.02
Z- effect	1	
Inadequate reduction	3	
Varus deformity	1	

Table III shows that complications were failure to insert distal screw in 2, Z- effect in 1, inadequate reduction in 3 and varus deformity in 1 case. The difference was significant ($P < 0.05$).

Discussion

Intertrochantric fractures are low energy trauma fractures seen in elderly and osteoporotic bones.⁷ Because of the high incidence of malunion, non-union and delayed union, there is limited role of conservative treatment for intertrochantric fractures.^{8,9} Extramedullary fixation of these fractures with implants like the dynamic hip screw or the dynamic condylar screw has potential disadvantages of extensive exposure, more blood loss which then leads on to problems in fracture union and also implant failure.¹⁰ Intramedullary fixation is more biological as this implant is inserted after closed reduction using a minimal invasive technique. Proximal femoral nail reduces the lever arm due to intramedullary location.^{11,12} The present study was conducted to assess role of proximal

femoral nail in management of intertrochantric femur fracture.

We found that out of 62 patients, males were 40 and females were 22. Endigeri et al¹³ evaluated the outcome of intertrochantric fractures treated with proximal femoral nailing by using Kyle's criteria. The study involved fifty cases of intertrochantric fractures of femur that were treated with PFN. Fractures were classified using Orthopaedic Trauma Association classification. Patients were followed up at 4 weeks, 3 months, and 6 months and results were evaluated using Kyle's criteria. The study included fifty patients, 32 males and 18 females of age 38-94 years with an average of 57 years. Excellent and good results were found in 44 patients (88%). Intra- and post-operative complications were found in 12 patients (24%).

We found that OTA fracture type was 31 A1 in 18, 31A2 in 24 and 31 A3 in 20 cases. Mode of injury was RTA in 36, fall in 15 and others in 11. Laterality was left in 34 and right in 28. Kyle's criteria was excellent in 30, good in 16,

fair in 14 and poor in 2 cases. Malik et al¹⁴ evaluated effectiveness and strength of proximal femoral nail with early mobilization and functional recovery of patient in management of fracture intertrochanteric femur. Forty patients with Fracture Intertrochanteric Femur were studied. Fractures are evaluated as stable and unstable fractures according to Modified Evan- Jensen classification. Majority of the patients were males (65%) and had age between 61-80 years (52.5%) with mean age of 71.58 ± 12.37 years. Majority of the patients had operative time more than equal to 1 hour. Harris Hip Score at 1 month was 71.10 ± 5.52 , while at 3 months it was 80.13 ± 7.97 . There was a statistically significant increase in the mean Harris Hip Score at 3 months in comparison to 1 month. The mean Harris Hip Score at 1 month was 71.10 ± 5.52 . There was a statistically significant increase in the mean Harris Hip Score at 6 months in comparison to 3 months

We found that complications were failure to insert distal screw in 2, Z- effect in 1, inadequate reduction in 3 and varus deformity in 1 case. Reska et al¹⁵ reported an incidence of deep vein thrombosis in 1.2%. Study done by Chidanand et al¹⁶ showed superficial infection in 4.5% cases and Z effect in 2.2%.

The limitation the study is small sample size.

Conclusion

Authors found that proximal femoral nail is a good minimally invasive stable fixation option with minimal soft tissue handling for unstable intertrochanteric fractures. Patients treated by proximal femoral nailing showed good functional outcome.

References

1. Dordevic N, Stanojilovic M, Milenkovic S, Stojiljkovic P, Kocic M, Golubovic I. Perioperative and early postoperative outcome of proximal femoral nailing for stable and unstable trochanteric fractures. *Acta facultatis medicae Naissensis*. 2016; 33 (1):43-7.
2. Kumar A, Somashekareappa T, Singh A, Narula RK. Proximal femoral nail still of implant of choice in trochanteric fracture. *International Journal of Contemporary Medical Research*. 2016;3(7):1967-9.
3. Aithala JP, Rao S. Proximal Femoral Nailing: Technical difficulties and results in Trochanteric Fractures. *Open Journal of Orthopedics*. 2013;3:234-42.
4. Korkmaz MF, Erdem MN, Disli Z, Selcuk EB, Karakaplan M, Gogus A. Outcomes of trochanteric femoral fractures treated with proximal femoral nail: An analysis of 100 consecutive cases. *Clin Interv Aging*. 2014;9:569-74.
5. Ravishankar J, Puneeth, Mahida JR. A prospective study to evaluate the radiological and functional outcome of unstable intertrochanteric fractures treated with proximal femoral nail. *International Journal of Orthopaedics Sciences*. 2016;2(4):302- 6.
6. Tank PJ, Solanki RA, Patel HA, Rathi N, Mistry J, Bhabhor HB, et al. Results of proximal femoral nail in intertrochanteric fracture of femur. *IOSR Journal of Dental and Medical Sciences (IOSR-JDMS)*. 2016;15(4):17-24.
7. Ghilzai AK, Shah SKA, Khan MA, Ghazi MA, Najjad MKR. Role of proximal femoral Nail in the treatment of unstable intertrochanteric fractures. *Biomed J Sci& Tech Res* 2018; 2(1):1.
8. Baumgaertner MR, Curtin SL, Lindskog DM. Intramedullary versus extramedullary fixation for the treatment of intertrochanteric hip fractures. *Clin Orthop Relat Res* 1998;348:87-94.
9. Gadegone WM, Salphale YS. Proximal femoral nail – An analysis of 100 cases of proximal femoral fractures with an average follow up of 1 year. *Int Orthop* 2007;31:403-8.
10. Pajarinen J, Lindahl J, Michelsson O, Savolainen V, Hirvensalo E.

- Pertrochanteric femoral fractures treated with a dynamic hip screw or a proximal femoral nail. A randomised study comparing post-operative rehabilitation. *J Bone Joint Surg Br* 2005;87:76-81.
11. Pavelka T, Houcek P, Linhart M, Matejka J. Osteosynthesis of hip and femoral shaft fractures using the PFN-long. *Acta Chir Orthop Traumatol Cech* 2007;74:91-8.
 12. Boldin C, Seibert FJ, Fankhauser F, Peicha G, Grechenig W, Szyszkowitz R. The proximal femoral nail (PFN) A minimal invasive treatment of unstable proximal femoral fractures: A prospective study of 55 patients with a follow-up of 15 months. *Acta Orthop Scand* 2003;74:53-8.
 13. Endigeri P, Pattanashetty OB, Banapatti DB, Pillai A, Ullas T. Outcome of intertrochanteric fractures treated with proximal femoral nail: A prospective study. *Journal of Orthopaedics, Traumatology and Rehabilitation*. 2015;8(1):25-9.
 14. Malik et al. A Retrospective and Prospective Study of Proximal Femoral Nail in Fracture Intertrochanteric Femur. *International Journal of Health and Clinical Research*, 2021;4(7):248-251.
 15. Reska M, Veverkova L, Divis P, Konecny J. Proximal femoral nail (PFN) – A new stage in the therapy of extracapsular femoral fractures. *ScriptaMedica (BRNO)*. 2006;79(2):115-22.
 16. Chidanand KJC, Avinash P, Sridhar DR, Rafeeq MD, Babu S. Prospective Analysis of Extracapsular Fractures of the Proximal Femur Treated with Proximal Femoral Nail. *Int J Sci Stud*. 2015;3(8):97-100.